

Case Report

Hemobilia. A case report

Gerardo Pasos-Altamirano, MD,¹ Hugo Mendieta-Zerón, MD,¹ Elizabeth Fuentes-Luitón, MD²

Abstract

We present the case of a 88 years old male, with a history of melena, demonstrated by repeated endoscopies to be secondary to hemobilia, and after endoscopic retrograde cholangiopancreatography we could demonstrate the presence of bleeding intraductal choledocus polyps with histopathological report of intraepithelial adenoma. Hemobilia is a rare cause of upper gastrointestinal hemorrhage with an increasing incidence because of the widespread use of invasive hepatobiliary procedures and improved recognition. In the majority of cases the cause is iatrogenic. The classical presentation of hemobilia is with biliary colic, jaundice, hematemesis, and melena. The diagnosis and evaluation of hemobilia is facilitated by the use of sonography, computed tomography and endoscopic retrograde cholangiopancreatography. Persistent bleeding sometimes requires urgent therapeutic intervention, such as angiography or surgery.

Key words: Adenoma, gastrointestinal hemorrhage, hemobilia, polyps.

Case report

We present the case of a 88 years old male, resident of Nuevo Leon, Mexico. He a medical history of cigarette smoking from the 16 to the 76 years old, and alcohol intake from 16 to 85 years old. Uncomplicated cholecystectomy by acalculous cholecystitis in 1996. In 1997 and 1998 the patient presented melena, requiring hemotransfusion medical treatment with omeprazol. Endoscopic diagnostic was gastritis and esofagitis. In 1999 the endoscopic diagnostic of hemobilia was made. In 2001, he was treated in Monterrey, Nuevo Leon, Mexico for incre-

ment in the frequency of melenic evacuations, and severe weakness that disabled him to carry out his normal activities. His symptoms were accompanied with dyspnea. He was referred to National Medical Center "20 de Noviembre", ISSSTE, Mexico for his treatment.

The physical examination revealed temperature of 36.4°C, the pulse was 80, and the respirations were 18. The blood pressure was 110/60 mmHg. Pale, without neurologic affection, normal cardiac exploration, there was no rebound tenderness or Murphy's sign, there were no abdominal masses and bowel sounds were normal.

A digital rectal examination was positive to melena. All the laboratory tests were normal, except hemoglobin was 7.5 mg/dL, glucose of 187.6 mg/dL and albumin of 1.7 g/dL. While hospitalized a new gastroscopy showed polyps of the duodenum. The endoscopic retrograde cholangiopancreatography (ERCP) showed, images suggesting intraductal choledocus polyps, as well as dilation of choledocus and intrahepatic bile ducts, being subjected to surgery exploration observing polyps in the left hepatic duct, taking a biopsy that reported intraepithelial adenoma (*Figure 1*). His evolution was torpid, presenting data of obstructive jaundice, and manifestations of hepatic encephalopathy that remitted with medical treatment. It is presented as rare case of hemobilia due to intraepithelial adenoma of polyps inside the choledocus.

Discussion

Hemobilia is an uncommon cause of upper gastrointestinal hemorrhage. Its incidence has increased in recent years because of the widespread use of invasive hepatobiliary procedures¹ and improved recognition. The term hemobilia was first used by Sandblom to describe bleeding into the biliary system after a subcapsular liver injury,² but this term is now used to describe bleeding into the biliary system from any cause, although many investigators only consider bleeding lasting longer than 24 hours.³ Mild to moderate hemobilia is defined as bleeding that resolved within 48 hours and do not necessitate transfusion. Severe hemobilia is considered with hemorrhage resulting in hemodynamic instability or necessitating transfusion.

In the majority of cases the cause is trauma, iatrogenic (liver biopsy, percutaneous transhepatic cholangiography), with the mean period to onset of bleeding after accidental hepatic trauma of 4 weeks,¹ infections (typically parasitic), tumors, inflammatory disorders, and gallstones, other caus-

¹ Department of Internal Medicine.

² Department of Pathology.

National Medical Center "20 de Noviembre". ISSSTE. Mexico City, Mexico

Address for correspondence:

Hugo Mendieta-Zerón, MD

Felipe Villanueva sur 1209, Colonia Rancho Dolores 50170, Toluca, Mexico, Tel: 01-722-2176605, Cel: 0445531184490

E-mail: mezh_74@yahoo.com

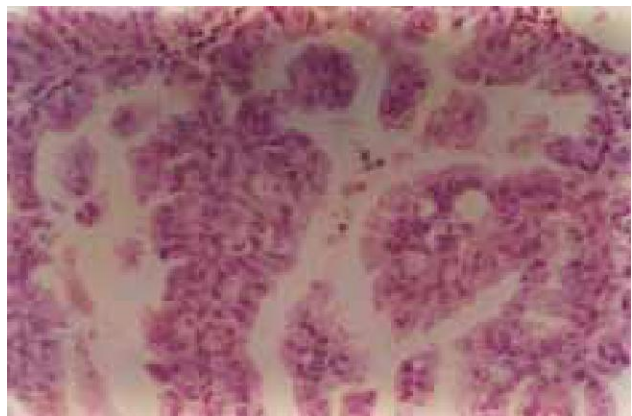


Figure 1. Photomicrography of the polyps (Hematoxylin and eosin ×300).

es are vascular diseases such as aneurysm, and bleeding disorders.⁴ Bismuth published a review with 55 well-documented cases of hemobilia,⁵ 53% originated in the liver, 23% in the gallbladder (almost all related to gallstones), 22% in the bile ducts, and 2% in the pancreas. Hemobilia can be a complication of transhepatic biliary drainage, transient and clinically insignificant or quite serious and mortal.³ This complication is explained by a biliary-vascular communication within a tract prior to biliary drainage catheter placement.⁶ Less common causes are pseudoaneurysm of the hepatic artery.⁷

Clinical presentation varies and may be intermittent. Hemobilia classically presents as biliary colic, jaundice, hematemesis, and melena. However, most patients do not present with all four of these findings.¹ Blood may clot in various locations depending on the amount and rate of bleeding,⁸ hematemesis or melena may occur. If the bleeding is brisk or the blood does not clot in the biliary tract. If blood clots within the bile duct, it may cause obstructive jaundice or pancreatitis.

Hemobilia is a rare condition. Acute biliary symptoms and signs combined with acute upper gastrointestinal bleeding should strongly suggest the possibility. The diagnosis and evaluation of hemobilia is facilitated by the widespread availability of new imaging techniques.⁴ Imaging studies such as sonography and computed tomography are helpful in assessing the possibility of tumor or stone disease. Magnetic resonance imaging can distinguish blood from stones and sludge and may be helpful when the diagnosis is uncertain. The diagnosis of hemobilia is most frequently made by upper endoscopy or ERCP, but may also be made by nasobiliary aspiration, percutaneous transhepatic cholangiography, or angiography.⁹ If bile duct obstruction is suspected, early ERCP is advisable. Angiography should be considered early in cases of trauma or known tumor for both diagnosis and therapy, it is useful in localizing the site of bleeding.

The cause of hemobilia must be corrected. Persistent bleeding sometimes requires urgent therapeutic intervention, such as angiography or surgery.¹⁰ In cases of hemorrhagic cholecystitis, surgery is obviously curative. In case of hemobilia during transhepatic biliary drainage treatment begins with assessment of catheter position. Fistulous communication of the biliary tree with a portal or hepatic vein branch can usually be managed by upsizing the drainage catheter with resultant tamponade of the bleeding site.¹¹

Hemobilia from a hepatic artery source frequently requires transcatheter embolization via a right femoral artery approach or even hepatic artery ligation, which can result in liver failure in patients with underlying hepatic insufficiency.¹² Angiography may provide an opportunity for arterial embolization¹³ which can be a simple, safe, and effective treatment for hemobilia¹⁴ with less morbidity and mortality than surgery.¹⁵

References

1. Yoshida J, Donahue PE, Nyhus LM. Hemobilia: review of recent experience with a worldwide problem. *Am J Gastroenterol* 1987; 82: 448-453.
2. Sandblom P. Hemorrhage into the biliary tract following trauma—"traumatic hemobilia". *Surgery* 1948; 24: 571-586.
3. Monden M, Okamura J, Kobayashi N, Shibata N, Horikawa S, Fujimoto T, Kosaki G, et al. Hemobilia after percutaneous transhepatic biliary drainage. *Arch Surg* 1980; 115: 161-164.
4. Bloechle C, Izbicki JR, Rashed MY, El-Sefi T, Hosch SB, Knoefel WT, Rogiers X, et al. Hemobilia: presentation, diagnosis, and management. *Am J Gastroenterol* 1994; 89: 1537-1540.
5. Bismuth H. Hemobilia. *N Engl J Med* 1973; 288: 617-619.
6. Goodwin SC, Bansai V, Greaser LE, Stainken BF, McNamara TO, Yoon H. Prevention of Hemobilia during percutaneous biliary drainage: long-term follow up. *Journal of Vascular and Interventional Radiology* 1997; 8(5): 881-883.
7. Cattani P, Cuillerier E, Cellier C, Cuenod CA, Roche A, Landi B, Barbier JP. Hemobilia caused by a pseudoaneurysm of the hepatic artery diagnosed by EUS. *Gastrointest Endosc* 1999; 49(2): 252-255.
8. Kroser J, Rothstein RD, Kochman ML. Endoscopic management of obstructive jaundice caused by hemobilia. *Gastrointest Endosc* 1996; 44: 618-619.
9. Cappell MS, Marks M, Kirshcenbaum H. Massive hemobilia and acalculous cholecystitis due to benign gallbladder polyp. *Dig Dis Sci* 1993; 38: 1156-1161.
10. Sandblom P. Iatrogenic hemobilia. *Am J Surg* 1986; 151: 754-758.
11. Mitchell SE, Shuman LS, Kaufman SL, Chang R, Kadir S, Kinnison ML, White RI Jr. Biliary catheter drainage complicated by hemobilia: treatment by balloon embolotherapy. *Radiology* 1985; 157: 645-652.
12. Okazaki M, Ono H, Higashihara H, Koganemaru F, Nozaki Y, Hoashi T, Kimura T, et al. Angiographic management of massive hemobilia due to iatrogenic trauma. *Gastrointest Radiol* 1991; 16: 205-211.
13. Curet P, Baumer R, Roche A, Grellet J, Mercadier M. Hepatic hemobilia of traumatic or iatrogenic origin: recent advances in diagnosis and therapy, review of the literature from 1976 to 1981. *World J Surg* 1984; 8: 2-8.
14. Walter JF, Paaso BT, Cannon WB. Successful transcatheter embolic control of massive hemobilia secondary to liver biopsy: case report. *AJR Am J Roentgenol* 1976; 127: 847-849.
15. Heimbach DM, Fergusson GS, Harley JD. Treatment of traumatic hemobilia with angiographic embolization. *J Trauma* 1978; 18: 221-224.